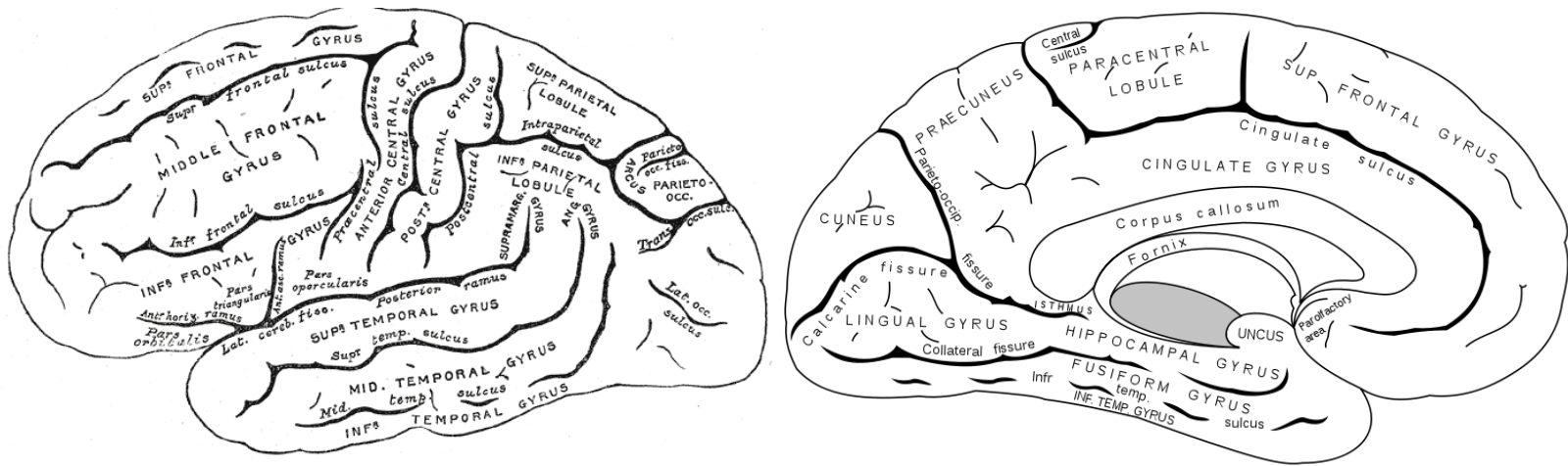




CEREBRAL LOCALIZATION

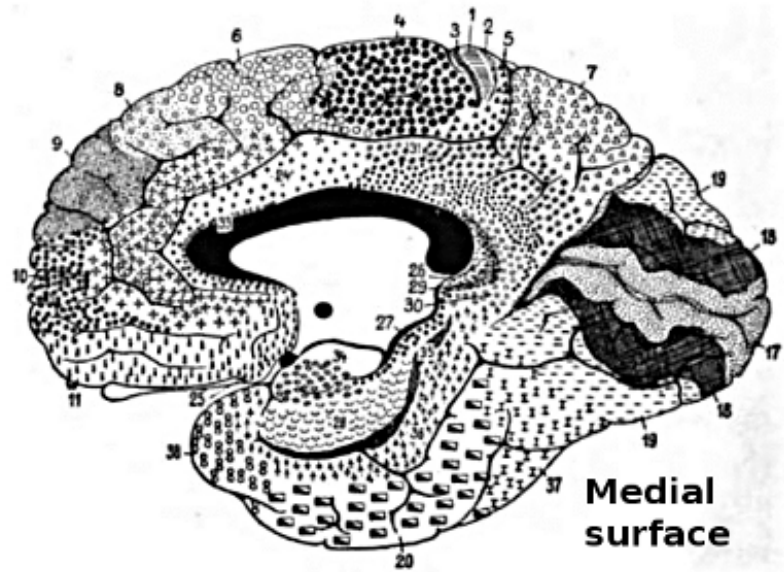
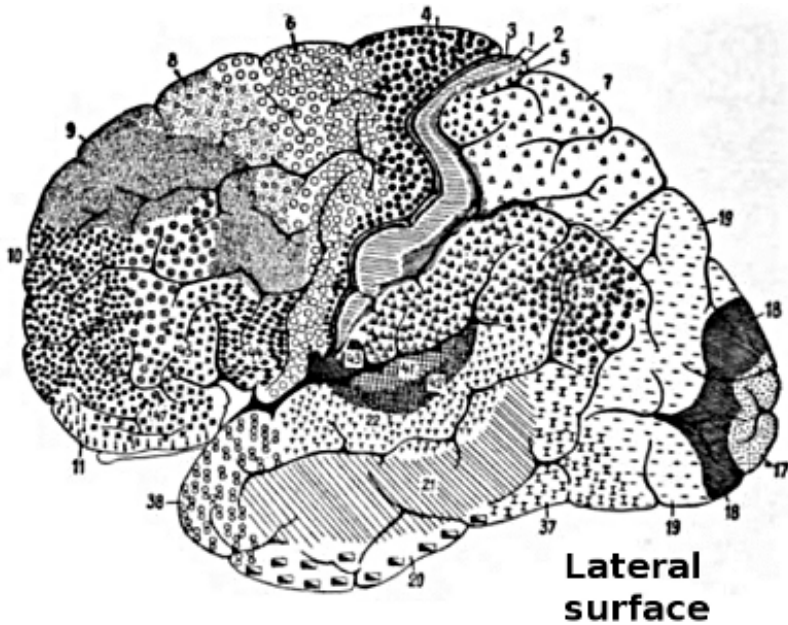
PARIETAL LOBE SIGNS

PARIETAL LOBE



File:Gray726,727.svg

BRODMANN AREAS



[wikimedia.org/wiki/commons/0/09](https://commons.wikimedia.org/wiki/File:Brodmann_areas_of_the_cerebral_cortex.jpg)

PARIETAL LOBE

- Special high order sensory organ
- Locus of transmodal (intersensory) integration
- Awareness of one's body & its relation to extra personal space and of objects in the environment to each other.

LESIONS OF PARIETAL LOBE

- Post central gyrus
 - Simple somatosensory disturbances
 - Contra lateral sensory loss (object recognition > position sense > touch > pain and temperature, vibration); tactile extinction
 - Contra lateral pain, paresthesias
- Mesial aspect (cuneus)
 - Transcortical sensory aphasia? (dominant hemisphere)
 - Attentional disorder

LESIONS OF PARIETAL LOBE

- In general,
 - left hemisphere is dominant for thought and reasoning, analytic and mathematical skills
 - the right hemisphere is dominant for tasks requiring spatial and constructional skills, as well as for directed attention and body image

LESIONS OF PARIETAL LOBE

- Lateral aspect (superior and inferior parietal lobules)
 - Dominant hemisphere
 - Parietal apraxia (higher lesion)
 - Finger agnosia
 - Acalculia
 - Right-left disorientation
 - Literal alexia (supramarginal gyrus)
 - Conduction aphasia

LESIONS OF PARIETAL LOBE

- Nondominant hemisphere
 - Anosognosia
 - Hemispatial neglect (sensory inattention)
 - Constructional apraxia
 - Dressing apraxia
 - Loss of topographical memory
 - Allesthesia
 - Hemisomatognosia
 - Asymbolia for pain

ANOSOGNOSIA

- Patients fail to recognize the hemiplegic limbs as belonging to them (anosognosia)
- and confabulate when asked whom they belong to (they often ascribe them to the examiner: somatoparaphrenia).
- Verbally acknowledging a problem but failing to be concerned is called anosodiaphoria.
- Rarely, patients may report a supernumerary phantom limb (phantom third limb or three arms) after right-hemisphere stroke.

LOSS OF TOPOGRAPHICAL MEMORY

- Visual or tactile localization of points in space and judgment of direction and distance are defective. Patients with right parietal lobe lesions tend to misplace the cities on a map and to get lost in familiar surroundings (loss of topographic memory)

ALLESTHESIA/ALLOKINESIA

- When stimulated on the side contra lateral to a hemisphere lesion, patients may demonstrate allesthesia, in which they misplace the location of the stimulus to the normal side.
- Patients with allokinesia respond with the wrong limb or move in the wrong direction

HEMISOMATOGNOSIA

- Patients with parietal lesions may demonstrate hemisomatognosia, which is a unilateral misperception of one's own body. This may be conscious (the patient feels like a hemiamputee) or unconscious (the patient behaves as a hemiamputee).

ASYMBOLIA FOR PAIN

- Patients with dominant parietal (especially supramarginal gyrus) or bilateral parietal lesions may demonstrate asymbolia for pain in which the patient does not react appropriately to pain and may indeed smile during painful stimuli

APRAXIA

- Inability to carry out well organized voluntary movement correctly despite the fact , that motor, sensory & coordinative functions are not significantly impaired.
- Pre-requisites
 - Intact motor system: to execute the act.
 - Intact sensorium : to understand the act.
 - Pt. comprehends & attempts to co-operate.
 - Pt.'s prev. skills were sufficient to perform the act.
 - Organic cerebral lesion as a cause of deficit.

APRAXIA VS OTHER MOTOR DEFICITS

- Pyramidal lesions : the paralysis precludes the act voluntarily or automatically.
- Cerebellar lesions : Patient retains the ability to perform the act but not smoothly.
- Basal ganglia lesions : Involuntary movements or rigidity impede the act but sequence of the act remains possible.

TESTING FOR APRAXIA

- Common apraxias :
 - Tongue apraxia : stick out your tongue
 - Hand apraxia : make a fist
 - Gait apraxia : walk across the room .
- If verbal instruction fails, try miming.
- More complicated apraxias :
 - Show how to light a cigarette, hammer a nail etc.

TESTING FOR APRAXIA

- Limb apraxia : 3 hand test :
 - 1) Make a fist & tap on the table with thumb pointing upwards
 - 2) Then straighten your fingers & tap on the table with thumb upwards
 - 3) Then place your palm flat on the table

TYPES OF APRAXIA

- Ideational : Patient is unable to initiate the action though understanding the command.
- Ideomotor : Patient performs the task but makes errors; there is a common tendency to substitute a body part for an object, e.g. using index finger as a toothbrush rather than pretending to hold one.

[Dominant supramarginal gyrus lesions]

TYPES OF APRAXIA

- Constructional apraxia : Unable to draw/copy geometric figures , clock face , 5 pointed star.
[Non-dominant angular gyrus lesions]
- Dressing apraxia : patient becomes hopelessly muddled in trying to dress & undress, puts clothes wrong way round.
[Non-dominant post. parietal lobe lesion]

AGNOSIA

- Abnormalities of perception of sensation despite normal sensory pathways.
- Can occur in all types of sensation but clinically usually affect vision, touch & body perception.
- Visual & body perception are impaired in parietal lobe lesions .

AGNOSIA IN PARIETAL LOBE LESIONS

○ SENSORY:

- Asterognosis : Ask pt. to close eyes & place an object : coin, key, in his hand & ask what it is.
- Agraphaesthesia : trace letters or numbers b/w 1-10 on the skin of palm using any blunt tip, such as cap end of ballpoint pen.

○ AGNOSIA OF BODY SCHEME

- AKA ASOMATOGNOSIA/AUTOTOPAGNOSIA

AGNOSIA IN PARIETAL LOBE LESIONS

- Inability to locate, identify & orient one's body parts.
- **FINGER AGNOSIA & R/L DISORIENTATION**
 - Ask the pt. to show index finger, ring finger..
 - Ask pt. to touch right ear with left index finger.
 - Cross your hands & ask which one is right.
 - Interlock your fingers & ask pt. to pick out various digits.

AGNOSIA IN PARIETAL LOBE LESIONS

○ GERSTMANN'S SYNDROME

- Finger agnosia both for own & examiner's fingers
- Acalculia
- Right-left disorientation
- Agraphia without alexia

[Dominant angular gyrus lesion]

AGNOSIA IN PARIETAL LOBE LESIONS

○ ANOSOGNOSIA

- Josef Babinski introduced this term to refer to a pt. with left hemiplegia & left sided sensory loss but he was unaware of his neurological deficits.

Pt. may even say that the limbs do not belong to him.

At the other end of scale there is phenomenon – **PHANTOM LIMB** , seen in amputees, with retention of whole body image after removal of one member, c/o pain & paraesthesiae.

AGNOSIA IN PARIETAL LOBE LESIONS

- LEFT SIDE HEMISPATIAL INATTENTION
 - Patient ignores persons, objects or any stimuli from the affected side, fails to dress that side, fails to eat food from that half of plate.
 - Testing for inattention :
 - Ask to draw symmetrical figures
 - LINE BISECTION TEST : Draw 20 cm line & ask pt. to bisect, he will mark it considerably to the right of center.

AGNOSIA IN PARIETAL LOBE LESIONS

○ SENSORY SUPPRESSION/EXTINCTION

- Tactile/visual/auditory inattention to simultaneous bilateral stimuli.
- Tactile: Brush cheek with wisp of cotton, one side then other side & then both sides at the same time
- Visual : Wiggle finger in pt.'s temporal field
- Auditory: Shake a bunch of keys

[Seen in CVA, cerebral atrophic lesions, sometimes in parietal lobe tumors]

PARIETAL STROKE- SENSORY SYNDROMES

- The Pseudo thalamic sensory syndrome consists of a faciobrachiocrural impairment of elementary sensation (touch, pain, temperature, and vibration) – in patients with inferior & anterior parietal stroke involving the parietal operculum, posterior insula, and, in most patients, underlying white matter.

PARIETAL STROKE- SENSORY SYNDROMES

- The cortical sensory syndrome : consists of an isolated loss of discriminative sensation (stereognosis, graphesthesia, position sense) involving one or two parts of the body in patients with superior & posterior parietal stroke.

PARIETAL STROKE- SENSORY SYNDROMES

- The atypical sensory syndrome : consists of a sensory loss involving all modalities of sensation in a partial distribution. Parietal lesions of varied topography are responsible for this clinical picture, which probably represents a minor variant of the two previous sensory syndromes.

LESIONS OF PARIETAL LOBE

- Effects of unilateral disease of the parietal lobe, right or left
 - Corticosensory syndrome and sensory extinction (or total hemianesthesia with large acute lesions of white matter)
 - Homonymous hemianopia or inferior quadrantanopia or visual inattention
 - Neglect of the opposite side of external space (far more prominent with lesions of the right parietal lobe).
 - Mild hemiparesis (variable), unilateral muscular atrophy in children, hypotonia, poverty of movement, hemiataxia (all seen only occasionally)

LESIONS OF PARIETAL LOBE

- Effects of unilateral disease of the dominant (left) parietal lobe (in right-handed and most left-handed patients) additional phenomena include
 - Disorders of language (especially alexia)
 - Gerstmann syndrome
 - Tactile agnosia (bimanual astereognosis)
 - Bilateral ideomotor and ideational apraxia

LESIONS OF PARIETAL LOBE

- Effects of unilateral disease of the nondominant (right) parietal lobe
 - Visuospatial disorders
 - Topographic memory loss
 - Anosognosia, dressing and constructional apraxias (these may occur with lesions of either hemisphere but more frequently and are of greater severity with lesions of the nondominant one)
 - Confusion
 - Tendency to keep the eyes closed, resist lid opening, and blepharospasm

LESIONS OF PARIETAL LOBE

- Effects of bilateral disease of the parietal lobes
 - Visual spatial imperception,
 - Spatial disorientation
- With all these parietal syndromes, if the disease is sufficiently extensive, there may be a reduction in the capacity to think clearly as well as inattentiveness and slightly impaired memory.



THANK YOU